

## PennHIP Report

Referring Veterinarian: Dr Marie-Christine Lefrancois  
Email: lefrancoism123@gmail.com

Clinic Name: Clinique Maguire Medecine Veterinaire  
Clinic Address: 150-1394 Ave Maguire  
Quebec, QC G1T 1Z3  
Phone:  
Fax:

## Patient Information

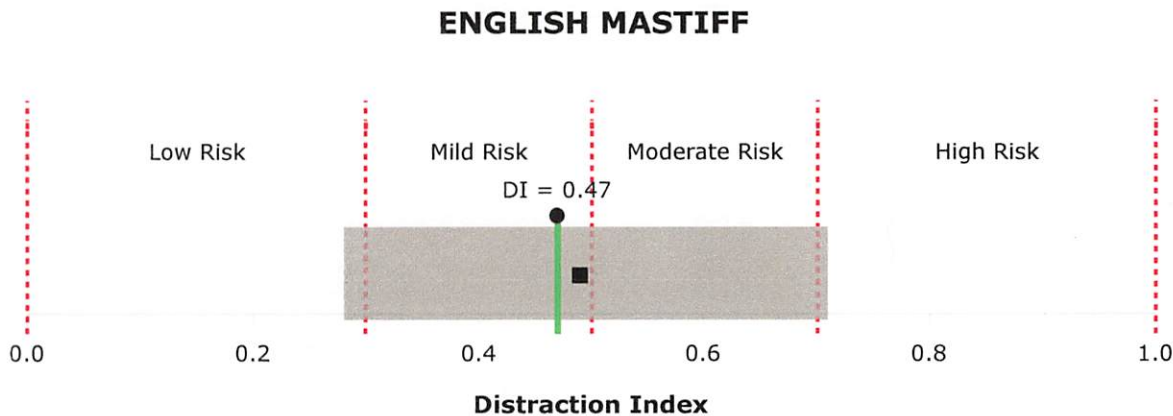
Client: PREMONT, Nathalie	Tattoo Num:
Patient Name: Naomi of Seven Oaks (GER)	Patient ID: 40403
Reg. Name:	Registration Num: FD-LA4269354
PennHIP Num: 197350	Microchip Num: 276095610996301
Species: Canine	Breed: ENGLISH MASTIFF
Date of Birth: 14 Jan 2023	Age: 12 months
Sex: Female	Weight: 119 lbs/54 kgs
Date of Study: 03 Jan 2024	Date Submitted: 05 Jan 2024
Date of Report: 07 Jan 2024	

## Finding:

Distraction Index (DI): Right DI = 0.45, Left DI = 0.47.  
Osteoarthritis (OA): **No radiographic evidence of OA for either hip.**  
Cavitation/Other Findings: No cavitation present.

## Interpretation

Distraction Index (DI): The laxity ranking is based on the hip with the greater laxity (larger DI). In this case the DI used is 0.47.  
OA Risk Category: The DI is between 0.31 and 0.49. This patient is at mild risk for hip OA.  
Distraction Index Chart:



**BREED STATISTICS:** This interpretation is based on a cross-section of 1193 canine patients of the ENGLISH MASTIFF breed in the AIS PennHIP database. The gray strip represents the central 90% range of DIs (0.28 - 0.71) for the breed. The breed average DI is 0.49 (solid square). The patient DI is the solid circle (0.47).